



Available online at
ScienceDirect
www.sciencedirect.com

Elsevier Masson France
EM|consulte
www.em-consulte.com/en



Review article

Post-traumatic knee stiffness: Surgical techniques



N. Pujol*, P. Boisrenoult, P. Beaufile

Service d'orthopédie, université Versailles-Saint Quentin, centre hospitalier de Versailles, 177, rue de Versailles, 78157 Le Chesnay, France

ARTICLE INFO

Article history:
 Accepted 29 June 2014

Keywords:
 Stiffness
 Arthroscopy
 Knee
 Arthrolysis

ABSTRACT

Post-traumatic knee stiffness and loss of range of motion is a common complication of injuries to the knee area. The causes of post-traumatic knee stiffness can be divided into flexion contractures, extension contractures, and combined contractures. Post-traumatic stiffness can be due to the presence of dense intra-articular adhesions and/or fibrotic transformation of peri-articular structures. Various open and arthroscopic surgical treatments are possible. A precise diagnosis and understanding of the pathology is mandatory prior to any surgical treatment. Failure is imminent if all pathologies are not addressed correctly. From a general point of view, a flexion contracture is due to posterior adhesions and/or anterior impingement. On the other hand, extension contractures are due to anterior adhesions and/or posterior impingement. This overview will describe the different modern surgical techniques for treating post-traumatic knee stiffness. Any bony impingements must be treated before soft tissue release is performed. Intra-articular stiff knees with a loss of flexion can be treated by an anterior arthroscopic arthrolysis. Extra-articular pathology causing a flexion contracture can be treated by open or endoscopic quadriceps release. Extension contractures can be treated by arthroscopic or open posterior arthrolysis. Postoperative care (analgesia, rehabilitation) is essential to maintaining the range of motion obtained intra-operatively.
 © 2014 Elsevier Masson SAS. All rights reserved.

1. Introduction

Knee stiffness, or more accurately, a limitation in range of motion, is a potential complication after any intra-articular or extra-articular injury. It can be caused by a flexion contracture, an extension contracture or a combined contracture (affecting both flexion and extension) relative to the contralateral side (if healthy).

This stiffness has two components:

- intra-articular: tissue remodeling [1] leading to intra-articular adhesions, excessive proliferation of fibrous scar tissue, retraction of peri-articular soft tissues and bone impingement due to intra-articular malunion;
- extra-articular: quadriceps adhesions to a femoral callus, femoral aponeurosis and intermuscular septum, retraction of the muscle due to scar tissue and skin adhesions in the deeper layers.

Depending on the nature of the initial injury and the treatments applied, these two components will be present in variable amounts [2].

Treatment consists of analyzing the condition and then surgically releasing certain anatomical structures as needed. Various open and arthroscopic surgical techniques have been used over the past 30 years to treat all of the causes of stiffness while reducing morbidity [3,4]. We will sequentially review the causes of stiffness, the various techniques used to address them and their indications.

2. Analysis of stiffness

It is important to determine the source of the stiffness, as this information will determine which procedures should be performed and the prognosis. Adhesion and bone impingement are the key words. In all cases of post-traumatic stiffness, any fractures must be healed before release can be performed, thus, a 3–6-month waiting period is required. The surgeon must compromise between managing stiffness and obtaining bone union. Moreover, any complex regional pain syndrome (CRPS) must be detected. If the condition does not resolve spontaneously, surgery should only be performed during the quiet phase. Surgery must be delayed if active CRPS is suspected. However, it is hard to distinguish between post-traumatic stiffness and CRPS, since these two conditions are often interlinked. The signs of CRPS (warm, inflamed knee; pain that is not relieved by analgesics; stiffness that persists or gets worse) are in direct contrast with those of a non-swollen knee that is moderately painful and has undergone progressive changes in range

* Corresponding author. Tel.: +33 1 39 63 89 51; fax: +33 1 39 63 95 07.
 E-mail address: npujol@ch-versailles.fr (N. Pujol).

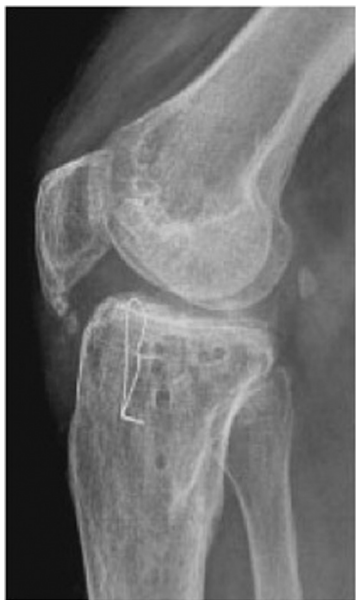

Fig. 1. Post-traumatic patella baja is responsible for loss of flexion.

of motion over time (up to a certain point). There will be an area of increased uptake on bone scan for several months after a fracture. A progressive reduction of this uptake is a sign that CRPS will resolve. MRI can be useful in these cases. But, it should be kept in mind that the results of mobilization procedures are not as good beyond 6 months.

2.1. Loss of flexion

In cases of limited flexion, one must look for posterior impingement (femoral malunion), anterior adhesions or retractions (joint capsule, quadriceps bursa, patellar retinaculum, quadriceps), and patella baja/inferior. Recent knee radiographs are essential: A/P and lateral weight bearing, Schuss view, 30° flexion view of patellofemoral joint. Radiographs of the femur are also needed if it was fractured, along with long-leg standing views. CT arthrography and/or MRI can be useful in characterizing the reasons for stiffness. These can help determine the presence of intra-articular malunion, the capsule volume, and the presence of meniscus, cartilage and ligament injuries. Patellar height is measured using the Caton–Deschamps index [5]. Patella baja or inferior (index less than 0.6) is one of the main causes of limited knee flexion. It can be a direct consequence of the initial injury (Fig. 1) or the result of CRPS.

2.2. Loss of extension

In cases of limited extension (flexion deformity), one must look for anterior impingement (e.g. malunion of the intercondylar eminence), contracture of anterior cruciate ligament (ACL) and posterior cruciate ligament (PCL) (retraction of the PCL, which is taut during flexion, primarily limits flexion, unless the PCL insertions were brought closer together due to malunion, in which case, the PCL will also limit extension) (Fig. 2), and contracture of the posterior joint capsule over the condyles. This posterior capsule contracture may be asymmetric; it can be analyzed on axial slices of the CT arthrography (or MRI in cases of significant swelling) by determining the posterior joint volume (Fig. 3). An ACL contracture is more difficult to evaluate; it is often revealed during arthroscopy. A contracture of the gastrocnemius muscles may also be present. It can be detected during the clinical exam by looking for a change in the flexion deformity when the ankle is maximally dorsiflexed. If a

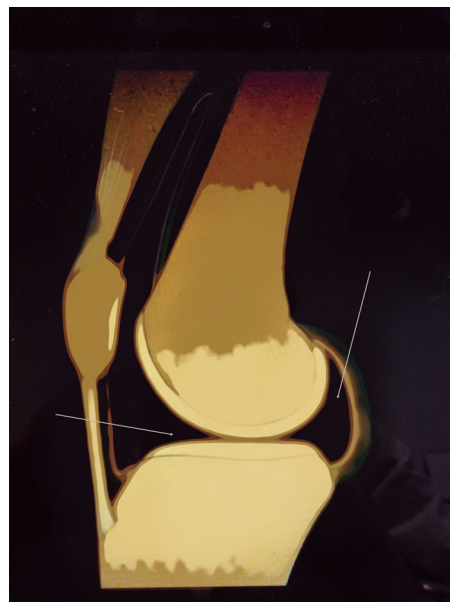


Fig. 2. Anterior impingement or posterior adhesions are the cause of extension-limiting stiffness.

contracture exists in the gastrocnemius, the maneuver will increase the knee's passive flexion deformity. If this occurs, gastrocnemius release may be needed.

2.3. Other components

2.3.1. Was the initial injury purely intra-articular (patella fracture, Hoffa's syndrome, immobilized severe knee sprain, etc.), purely extra-articular (mid-shaft femur fracture) or both?

This contributes to determining if the stiffness has intra-articular, extra-articular or combined origins, respectively.

2.3.2. Was the initial injury closed or open?

If it was open, where the soft tissue severely damaged? A large open femoral shaft fracture with adhered, retracted scar tissue is a

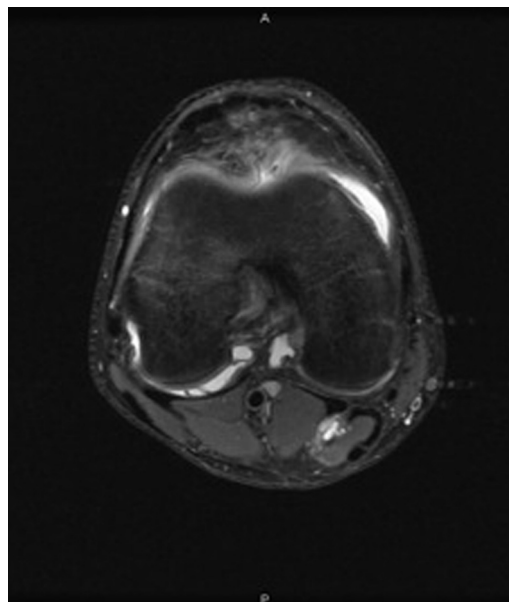


Fig. 3. Asymmetric appearance of the posterior joint capsule due to medial contracture (MRI, axial view).

Table 1
Average results according to the technique used.

Loss of flexion	Average preoperative flexion	Average postoperative flexion at follow-up
Arthroscopic arthrolysis [6]	66°	117°
Isolated endoscopic quadriceps release [7]	60°	120°
Open quadriceps release [8]	30°	95°
Loss of extension	Average preoperative extension deficit	Average postoperative extension deficit at follow-up
Arthroscopic posterior release [1]	26°	3°
Open posterior release [9]	17°	2°

sign of quadriceps adhesions to the femur, which crossed through the quadriceps and skin at the time of the injury.

2.3.3. How long ago did the initial injury occur?

The more chronic the injury, the less the previous rules apply. Pure intra-articular stiffness will be complicated over time by quadriceps contracture; pure extra-articular stiffness will be complicated over time by intra-articular adhesions and capsule and ligament contractures.

2.3.4. Does the joint have signs of malunion and/or post-traumatic osteoarthritis?

In these cases, there is greater uncertainty around the outcome of a mobilization procedure. This is an essential prognostic factor and also a main component of the indication. In the most serious cases, arthroplasty can be performed right away, especially if the intra-articular malunion (or osteoarthritis) is significant and the patient is older. This type of case will not be discussed going forward, as this review will focus on cases of stiffness when the joint outline is normal or minimally disrupted.

3. Surgical techniques

We will describe the treatment for loss of flexion and then loss of extension using open and arthroscopic techniques. These can complement each other and also be synergistic. Postoperative pain management will be planned by the anaesthesia and surgical teams before the procedure. It is essential to plan for postoperative regional anaesthesia, ideally using a crural or even a sciatic catheter to allow for immediate rehabilitation. A morphine pump can be proposed. The expected outcomes for each type of procedure are summarized in Table 1.

3.1. Manipulation under anaesthesia

There is practically no use anymore for manipulation under anaesthesia (MUA), no matter how much time has elapsed since the injury event. It is fraught with many potential problems: fracture, failure of fixation construct, tendon rupture, cartilage damage, etc. Nevertheless, gentle manipulations can be an option before 3 months, for example, after IM nailing of an isolated femoral shaft fracture with radiological signs of union, because the contractures are not yet severe and the risk of fixation failure is low.

3.2. Anterior arthroscopic arthrolysis for loss of flexion

This is now a standard technique that can be considered starting 3 months after the injury event, and sometimes earlier [10]. In fact, it should be suggested early on if the joint range of motion is no longer improving and there are no signs of active CRPS. Any fractures must have healed.

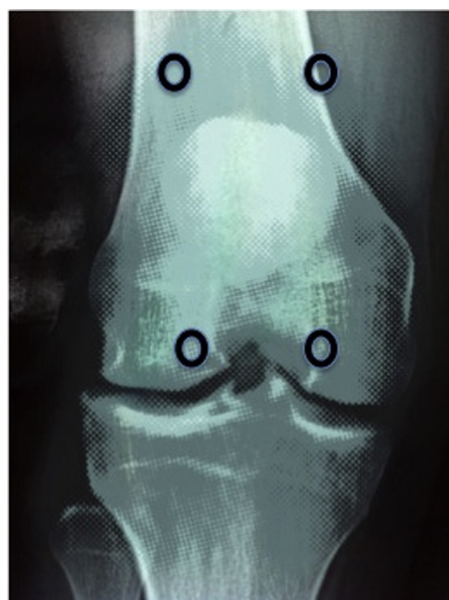

Fig. 4. Standard arthroscopic portals for anterior arthrolysis.

3.2.1. Patient positioning

The patient is placed supine with a tourniquet cuff placed at the base of the thigh and inflated to 300 mmHg. The range of motion is assessed again under general anaesthesia. The arthroscopy procedure requires a tower with arthroscopy pump, motorized shaver, electrocautery probe, Mayo scissors, clamps and basket forceps. The main arthroscopic release procedures for the knee, which were reviewed during a symposium of the French Arthroscopy Society (SFA) about 10 years ago, are still relevant [6].

3.2.2. Surgical approach

Standard anteromedial and anterolateral arthroscopic portals are made with the knee flexed; the scope is introduced into the suprapatellar area with the knee extended. Medial and lateral suprapatellar portals can be added as needed (Fig. 4). The suprapatellar bursa, which is often the source of adhesions (Fig. 5), is then released using electrocautery or a shaver down to the anterior femoral cortex, until the deep fibres of the quadriceps are clearly visible (Fig. 6). Any excess fibrous tissue is excised, along with the anterior synovial membrane. The retracted patellar retinaculum and adhesions to the femoral cortex (Fig. 7) are then

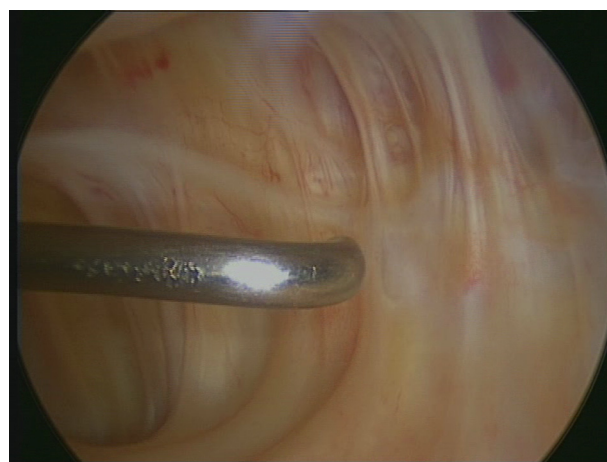


Fig. 5. Adhesions to the suprapatellar fat pad.

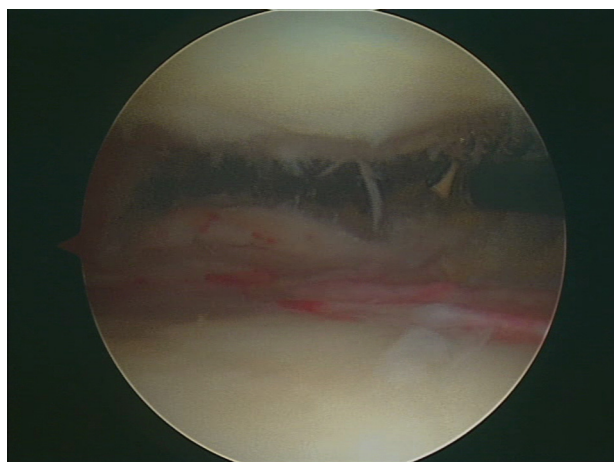


Fig. 6. Release of adhesions to the suprapatellar fat pad.

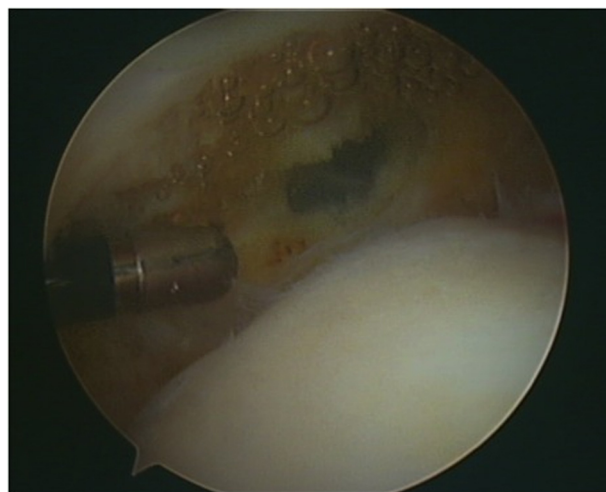


Fig. 8. Release of the posterior joint capsule.

extensively divided (ideally using electrocautery to limit postoperative bleeding) practically up to the subcutaneous tissue. The lateral retinaculum is typically the first structure to be released (Fig. 8). The anteromedial portal is used for the scope and the lateral suprapatellar and infrapatellar portals are used for the instruments. The scope and instrument portals are reversed to divide the medial retinaculum. This division can be completed using Mayo scissors, with one blade placed in the subcutaneous space and the other inside the joint. Any adhesions on the lateral femoral cortex are also released [11]. The knee is then flexed 45° and the notch freed up. In particular, the infrapatellar (Hoffa's) fat pad will need to be released from the tibia and the front of the intermeniscal ligament.

During the final intra-articular assessment, no significant adhesions must remain. Each step of the release procedure has an important role: release of suprapatellar bursa, division of retinaculum, freeing up of femoral cortex and anterior side of notch, release of fat pad adhesions. They are almost always performed in a systematic manner.

The irrigation liquid is then drained from the joint. At this point, and only at this point, gradual and reasonable mobilization can be carried out to further increase the range of motion. This is done after having released the tourniquet, so as to slacken the quadriceps, but before adding a lightly compressive bandage over the joint. It is recommended to palpate the patella and patellar tendon with one hand, and then to gradually flex the knee to let any remaining adhesions release themselves. Nevertheless, excessive force should not

be used as this may lead to fracture (femur, patella, tibia), patellar tendon avulsion, chondral damage due to excessive pressure, etc. After these manipulations, the maximum range of motion possible using the limb's weight is recorded (Fig. 9), along with the maximum passive range of motion. The final objective after rehabilitation is to at least match the flexion found using the limb's weight. In practice, it is rare to achieve more. The incisions are closed and a suction drain placed inside the joint. It is removed 2 or so days after the surgery, depending on its flow.

3.3. Open release for loss of flexion

The intra-articular causes of loss of flexion are now almost exclusively treated by arthroscopy with good results [12–15]. As a consequence, open release is reserved for knee stiffness cases that have a significant extra-articular component (quadriceps contracture and/or adhesions). The indications are now limited to sequelae of open femur fracture, femoral osteomyelitis, and femur shaft malunion. The surgeon must still be aware of how to perform quadriceps release techniques, which may be necessary in cases of major stiffness. This is a very extensive procedure. Hence, the expected benefits must be weighed against its risks (haemorrhage, haematoma, infection, repeated fracture, recurrence of stiffness, etc.) before starting.

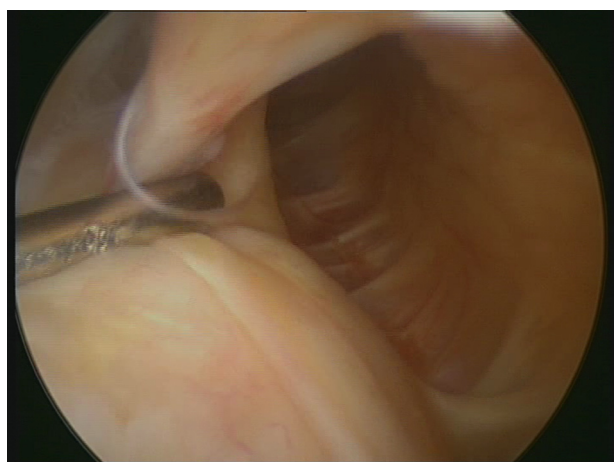


Fig. 7. Contracture of the patellar retinaculum.

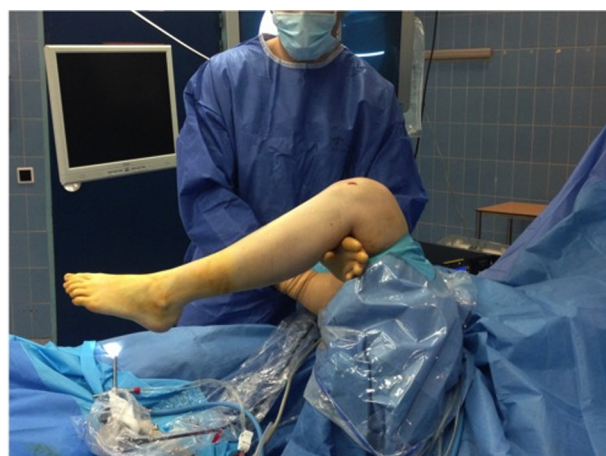

Fig. 9. Postoperative measurement of the range of motion using the limb's weight after the tourniquet has been released.

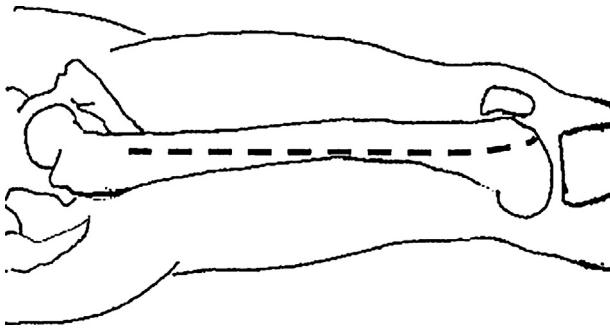


Fig. 10. Lateral approach used for quadriceps release.

3.3.1. Patient positioning

The patient is placed in a slight $\frac{3}{4}$ supine position with a cushion under the ipsilateral buttock and counter-support pad against the contralateral greater trochanter. The procedure is performed without a tourniquet for the quadriceps phase. A sterile tourniquet is useful during the first intra-articular phase. The operative field encompasses the entire lower limb so as to provide access to the hip at the end of the procedure, if needed.

3.3.2. Arthrolysis

Even if the stiffness is thought to have an extra-articular source, a tailor-made intra-articular release will be performed in the first phase to cut away any intra-articular adhesions. In the ideal case, this phase will be performed arthroscopically according to the aforementioned principles. In many cases, this will improve the range of motion by dozens of degrees. If this improvement is not sufficient, quadriceps release will be carried out next.

3.3.3. Open quadriceps release

This procedure was first described in 1956 by Robert and Jean Judet; it is performed through a wide lateral approach [7] (Fig. 10). The goal is to re-establish the sliding planes of the anterior thigh compartment. A longitudinal incision is made into the fascia lata and any adhesions between it and the quadriceps are released. The vastus lateralis muscle is detached from its aponeurosis and the linea aspera. Perforating blood vessels are coagulated or ligated. The vastus lateralis and intermedialis are completely detached from the femoral shaft. Judet recommended not releasing the muscle down to the bone and leaving fibrous tissue on the deep aspect of the muscle, but instead sectioning the muscle fibres with a scalpel and leaving the fibrous tissue on the bone. If the release is performed down to the bone, the fibrous tissue on the deep aspect of the quadriceps must then be excised to restore its flexibility.

Quite often, this release is not sufficient, which requires additional procedures:

- the vastus lateral tendon is detached under the greater trochanter. This provides access to the anterior and medial part of the femur by detaching the vastus medialis muscle (Fig. 11);
- if there is large amount of palpable tension in the tendon of the rectus femoris when the knee is maximally flexed, this tendon needs to be divided. The incision is extended superiorly and anteriorly and the rectus femoris tendon dissected free before being divided;
- in some cases, it may be necessary to section the anterior half of the vastus intermedialis aponeurosis in the middle part of the thigh.

The various steps of this quadriceps release are performed little by little and as needed based on the intra-operative observations. The incisions are closed with the knee in maximum flexion, so as

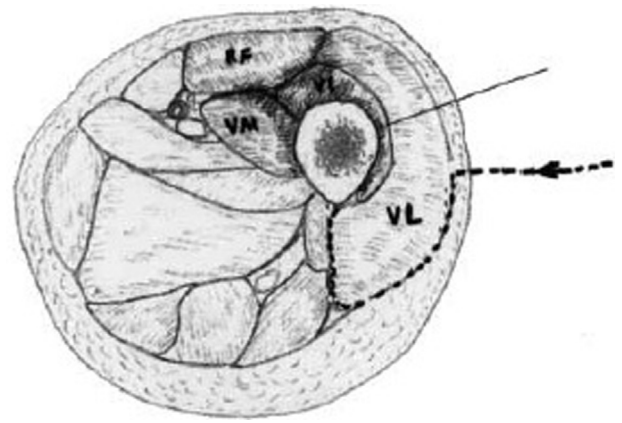


Fig. 11. Retrovastus approach of the femoral shaft.

to lose the least amount of flexion possible; division of the anterior half of the vastus intermedialis aponeurosis makes it possible to close the fascia lata above and below this cut.

The goal is to obtain at least 90–100° flexion using the limb's weight; this is a significant improvement in view of the preoperative flexion often being severely limited and averaging 25° in various published studies [8,16,17]. The flexion range of motion obtained using the limb's weight and then passively is recorded.

3.4. Endoscopic quadriceps release

In cases with combined intra- and extra-articular involvement, some authors have proposed doing an endoscopic release of quadriceps adhesions to the femur, in addition to the standard arthroscopic arthrolysis [18–20]. The outcomes seem satisfactory but there are certain limitations. The advantage of this technique is that it is less invasive and still allows for an open release procedure during the same step (conversion) if the arthroscopic results are not satisfactory. However, the indications have only been vaguely defined in published studies and there are no reliable recommendations as to the role of an endoscopic procedure relative to an open one.

3.5. Patella baja/infera

Acquired patellar baja (or infera) occurs when the patellar tendon is retracted due to scar tissue, adheres to the proximal end of the tibia, with contracture of the infrapatellar fat pad located on its posterior aspect [21]. This has also been called “infrapatellar contracture syndrome” [5,22]. It can severely restrict knee flexion.

Several procedures have been proposed for this condition: lengthening of patellar tendon [23] or even allograft reconstruction (if the tendon is too retracted to be lengthened) [24,25], but especially proximalization of the tibial tubercle [22]. The amount of proximalization needed to achieve a Caton–Deschamps index of 1 must be calculated; the patellar retinaculum must be extensively released down to the quadriceps, the infrapatellar fat pad resected and a standard tibial tubercle osteotomy performed. The strip should be 5–7 cm long and 2 cm wide. The tibial tubercle is raised 1.5 to 2 cm and secured 1 cm distal to the tibial plateau using two bicortical 4.5-mm diameter screws (Fig. 12). The procedure can be performed under fluoroscopy control. Immediate weight bearing is allowed while using a Zimmer splint; rehabilitation is initiated immediately; active extension is allowed after the first month; flexion is limited to 60° during the first 21 days and then up to 90° by the 45th day). This osteotomy can be performed in combination with soft tissue release in cases of severe patella baja.

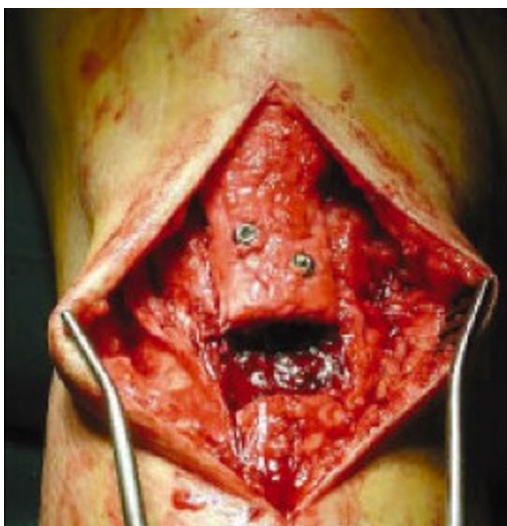

Fig. 12. Proximalization of the tibial tubercle for flexion contracture and patella baja.

3.6. Posterior arthrolysis for loss of extension

Once any anterior abutments have been eliminated, the reason for the loss of extension can be a posterior capsular contracture. This can be analyzed using axial MRI or CT arthrography slices by looking for adhesions of the posterior joint capsule, which can be asymmetric.

If an active patient has a persistent 10–15° flexion deformity that does not respond to conservative treatment and rehabilitation, arthrolysis seems justified. Open [9,26–28] and arthroscopic [19,29] techniques have been described. They will be summarized below.

3.7. Open posterior arthrolysis

A vertical posteromedial retroligamentous arthrotomy is carried out using a 4-cm incision with the knee flexed 90° (Fig. 13). Patient positioning assumes that an anterior arthrolysis was performed beforehand as needed to obtain sufficient flexion and posterior space, and to move any nerve and vascular structures away. The medial part of the posterior joint capsule is dissected from the femur and sectioned down to it. The posterior nervous and vascular elements are a notable distance away (more than 2 cm) when the knee is flexed 90° and we stay against the posterior aspect of the femur. The knee is then extended to determine if this release was effective. If it was not, a 4-cm long, lateral retroligamentous incision over the head of the fibula and in front of the biceps femoris tendon will be performed. After performing a retrocondylar arthrotomy, the capsule will be opened down to the femur. The lateral posterior capsule is then completely detached from the posterior aspect of the femoral metaphysis. At this point, gradual mobilization can be carried out to further increase the range of motion. The aponeurosis of the gastrocnemius muscles, and even the tendon insertions on the femur, can be divided at this stage as needed. The incisions are closed over an intra-articular drain left in place for at least 2 days (depending on the amount of bleeding) and then rehabilitation initiated immediately.

3.8. Arthroscopic posterior arthrolysis

This procedure is technically more challenging and requires good mastery of posterior arthroscopic approaches [30,31] (Fig. 14). The patient is placed with the knee flexed 90° and the foot resting

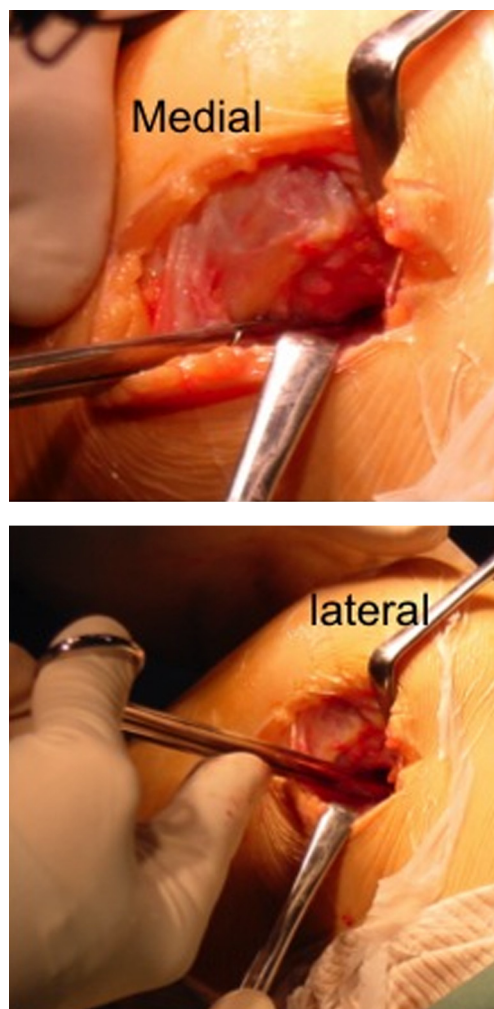


Fig. 13. Open posterior lateral and medial release.

against a pad. Anterior release is performed systematically first using standard anterior arthroscopy portals. Any impingement in the notch must be ruled out with the knee extended.

The scope is then introduced by the anterolateral portal under the posterior cruciate ligament (PCL) towards the posteromedial space. The posteromedial portal is located using a needle and

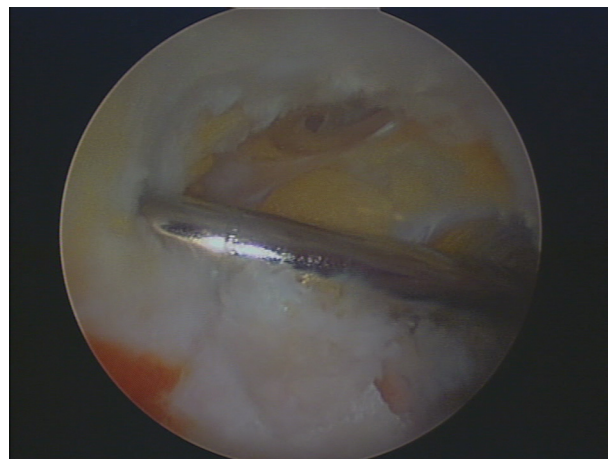

Fig. 14. Arthroscopic release of the posterior joint capsule through the posteromedial portal.

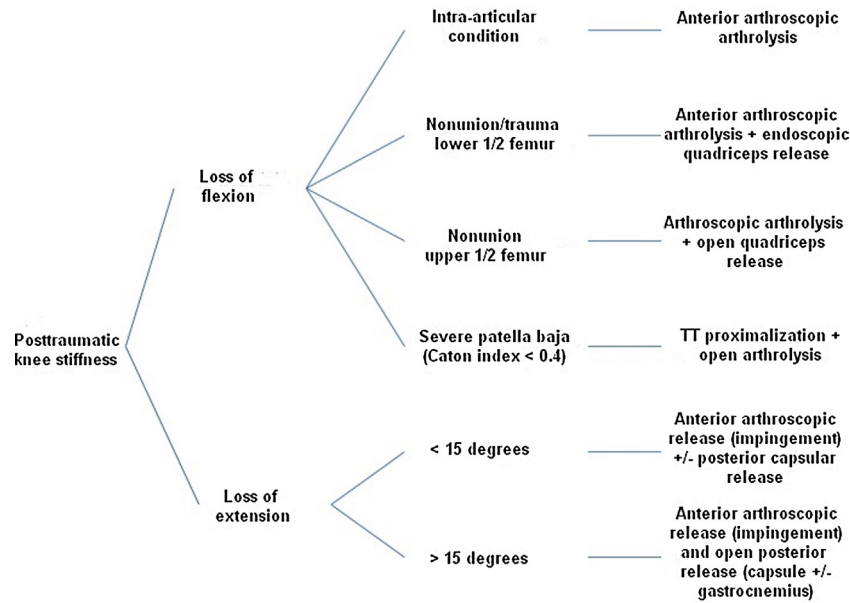


Fig. 15. Decision tree used by the Versailles (France) Orthopedic and Trauma Surgery Department for cases of post-traumatic knee stiffness without osteoarthritis or intra-articular malunion.

the scope's trans-illumination feature. The scope is then pointed upwards. The posterior capsule and adhesions are cut level with the femur surface using a motorized shaver or electrocautery probe until the fibres of the medial gastrocnemius muscle are visible.

As with an open procedure, the knee is extended to determine if this release was effective. If it was not, a posterolateral approach is made using back-and-forth movements from the posteromedial portal, through the intercondylar septum above the PCL, against the condyles with the knee flexed 90°. This technique was first described by Beaufils in 2003 [30] and is benign if performed correctly. The septum is excised to allow easier access to the posterolateral compartment. The capsule and lateral portion of the posterior joint capsule are sectioned down to the femur using the methods described previously. The gastrocnemius muscles can also be released at this point through arthroscopy. This is more of an opening of the deep surface of their aponeurosis. Gentle mobilization is the last step of the procedure. The incisions are closed over a suction drain placed inside the joint.

4. Postoperative recovery

4.1. Main principles

These include:

- limit the risk of postoperative haematoma by keeping the surgical drain in place long enough (at least 2 days), using a lightly compressive bandage early on and cold therapy multiple times every day. The risk of bleeding is high and the scar tissue induced by haematoma resorption increases the risk that stiffness will recur;
- start the rehabilitation with intermittent mobilization (when the patient arrives in the recovery room) and transfer the patient to a rehabilitation center on the 3rd postoperative day;
- combat pain effectively (catheter, morphine pump, analgesics, anti-inflammatory drugs, etc.) during, before and after the rehabilitation sessions.

All of these measures aim to stem the decrease in the range of motion that was obtained during the mobilization procedure. They are as important as the surgical procedure itself. Medical (surgeon,

anesthesiologist, physiatrist) and paramedical (physiotherapist, nurses) teams must pay particular attention to these patients and provide coordinated care. The surgeon must re-evaluate the patient's joint range of motion on a regular basis (every 15 days) to guide the rehabilitation protocol. This protocol must be aggressive enough to maintain the initial result.

4.2. After extension release

Rehabilitation is undertaken right away, with intermittent mobilization using a knee continuous passive motion (CPM) unit, extension postures (several hours per day, as tolerated), repeated static quadriceps contractions and wear of an extension brace at night.

4.3. After flexion release

Rehabilitation is undertaken right away with a CPM unit for 3–6 h per day with the flexion range set to the value obtained using the limb's weight under anaesthesia. Manual passive flexion maneuvers and isometric toning work for the quadriceps and hamstring muscles are also carried out.

5. Conclusions

Post-traumatic knee stiffness is a common condition. It requires an accurate assessment of the injuries. Any CRPS must be controlled and fracture sites must have healed. A 3 to 6-month wait seems reasonable before any release surgery is carried out, however the final decision is made on a case-by-case basis according to the clinical and imaging findings (Fig. 15).

There is practically no role for isolated manipulation under anaesthesia. Arthroscopic and open techniques can be used in combination within a well thought-out surgical plan to treat the various components of the stiffness in a single procedure. Drainage, control of postoperative pain and rehabilitation (early, daily, extensive and monitored) are essential to the success of this procedure. The final outcome will at best be equal to the one obtained using the limb's weight under anaesthesia, thus this value must be carefully recorded during the surgery.

Disclosure of interest

The authors declare that they have no conflicts of interest concerning this article.

References

- [1] Mariani PP, Santori N, Rovere P, Della Rocca C, Adriani E. Histological and structural study of the adhesive tissue in knee fibroarthrosis: a clinical-pathological correlation. *Arthroscopy* 1997;13(3):313–8 [Epub 1997/06/01].
- [2] Shelbourne KD, Patel DV, Martini DJ. Classification and management of arthrofibrosis of the knee after anterior cruciate ligament reconstruction. *Am J Sports Med* 1996;24(6):857–62 [Epub 1996/11/01].
- [3] Conti V. Arthroscopy in rehabilitation. *Orthop Clin North Am* 1979;10(3):709–11 [Epub 1979/07/01].
- [4] Sprague 3rd NF, O'Connor RL, Fox JM. Arthroscopic treatment of postoperative knee fibroarthrosis. *Clin Orthop Relat Res* 1982;166:165–72 [Epub 1982/06/01].
- [5] Caton J, Deschamps G, Chambat P, Lerat JL, Dejour H. [Patella infera. Apropos of 128 cases]. *Rev Chir Orthop Reparatrice Appar Mot* 1982;68(5):317–25 [Epub 1982/01/01]. Les rotules basses. À propos de 128 observations].
- [6] Hulet C, Djian P. [Stiffness of the knee joint – SFA 2002]. *Rev Chir Orthop Reparatrice Appar Mot* 2007;93(8 Suppl) [5S14–5. Epub 2008/04/05]. Les raideurs du genou – SFA 2002].
- [7] Jouffroy PJT. Libération de l'appareil extenseur selon Judet pour raideur sévère du genou en extension. *Encycl Med Chir, Éditions Scientifiques et Médicales, S. Paris: Elsevier SAS; 2000. p. 44–840* [Techniques chirurgicales–Orthopédie–Traumatologie].
- [8] Alici T, Buluc L, Tosun B, Sarlak AY. Modified Judet's quadricepsplasty for loss of knee flexion. *Knee* 2006;13(4):280–3 [Epub 2006/04/25].
- [9] Lobenhoffer HP, Bosch U, Gerich TG. Role of posterior capsulotomy for the treatment of extension deficits of the knee. *Knee Surg Sports Traumatol Arthrosc* 1996;4(4):237–41 [Epub 1996/01/01].
- [10] Achalandabaso J, Albillos J. Stiffness of the knee – mixed arthroscopic and subcutaneous technique: results of 67 cases. *Arthroscopy* 1993;9(6):685–90 [Epub 1993/01/01].
- [11] Vaquero J, Vidal C, Medina E, Baena J. Arthroscopic lysis in knee arthrofibrosis. *Arthroscopy* 1993;9(6):691–4 [Epub 1993/01/01].
- [12] Kim DH, Gill TJ, Millett PJ. Arthroscopic treatment of the arthrofibrotic knee. *Arthroscopy* 2004;20(Suppl 2):187–94 [Epub 2004/07/10].
- [13] Steadman JR, Dragoo JL, Hines SL, Briggs KK. Arthroscopic release for symptomatic scarring of the anterior interval of the knee. *Am J Sports Med* 2008;36(9):1763–9 [Epub 2008/08/30].
- [14] Dragoo JL, Miller MD, Vaughn ZD, Schmidt JD, Handley E. Restoration of knee volume using selected arthroscopic releases. *Am J Sports Med* 2010;38(11):2288–93 [Epub 2010/09/03].
- [15] Klein W, Shah N, Gassen A. Arthroscopic management of postoperative arthrofibrosis of the knee joint: indication, technique, and results. *Arthroscopy* 1994;10(6):591–7 [Epub 1994/12/01].
- [16] Lee DH, Kim TH, Jung SJ, Cha EJ, Bin SI. Modified judet quadricepsplasty and Ilizarov frame application for stiff knee after femur fractures. *J Orthop Trauma* 2010;24(11):709–15 [Epub 2010/10/01].
- [17] Warner JJ. The Judet quadricepsplasty for management of severe posttraumatic extension contracture of the knee. A report of a bilateral case and review of the literature. *Clin Orthop Relat Res* 1990;(256):169–73 [Epub 1990/07/01].
- [18] Wang JH, Zhao JZ, He YH. A new treatment strategy for severe arthrofibrosis of the knee. *Surgical technique. J Bone Joint Surg* 2007;89(Suppl. 2 Pt. 1):93–102 [Epub 2007/03/03].
- [19] Mariani PP. Arthroscopic release of the posterior compartments in the treatment of extension deficit of knee. *Knee Surg Sports Traumatol Arthrosc* 2010;18(6):736–41 [Epub 2009/09/29].
- [20] Dhillon MS, Panday AK, Aggarwal S, Nagi ON. Extra articular arthroscopic release in posttraumatic stiff knees: a prospective study of endoscopic quadriceps and patellar release. *Acta Orthop Belgica* 2005;71(2):197–203 [Epub 2005/09/13].
- [21] Paulos LE, Wnorowski DC, Greenwald AE. Infrapatellar contracture syndrome. Diagnosis, treatment, and long-term followup. *Am J Sports Med* 1994;22(4):440–9 [Epub 1994/07/01].
- [22] Drexler M, Dwyer T, Marmor M, Sternheim A, Cameron HU, Cameron JC. The treatment of acquired patella baja with proximalize the tibial tuberosity. *Knee Surg Sports Traumatol Arthrosc* 2013;21(11):2578–83 [Epub 2012/11/03].
- [23] Dejour D, Levigne C, Dejour H. [Postoperative low patella. Treatment by lengthening of the patellar tendon]. *Rev Chir Orthop Reparatrice Appar Mot* 1995;81(4):286–95 [Epub 1995/01/01]. La rotule basse postopératoire. Traitement par allongement du tendon rotulien].
- [24] Yoo JH, Chang JD, Seo YJ, Baek SW. Reconstruction of a patellar tendon with Achilles tendon allograft for severe patellar infera—a case report. *Knee* 2011;18(5):350–3 [Epub 2010/07/21].
- [25] Jeong JS, Wang JH. Treatment of patella infera by patellar tendon lengthening and augmentation with tibialis anterior tendon allograft. *Knee* 2013 [Epub 2013/11/16].
- [26] Lobenhoffer P, Gerich T, Hernandez R. [Therapy of extension deficits of the knee joint by arthroscopic arthrolysis and dorsal capsulotomy]. *Unfallchirurg* 1996;99(7):487–91 [Epub 1996/07/01]. Die Therapie von Streckdefiziten des Kniegelenks durch arthroskopische Arthrolyse und dorsale Kapsulotomie].
- [27] Millett PJ, Williams 3rd RJ, Wickiewicz TL. Open debridement and soft tissue release as a salvage procedure for the severely arthrofibrotic knee. *Am J Sports Med* 1999;27(5):552–61 [Epub 1999/09/25].
- [28] Freiling D, Lobenhoffer P. [The surgical treatment of chronic extension deficits of the knee]. *Oper Orthop Traumatol* 2009;21(6):545–56 [Epub 2010/01/21]. Die operative Behandlung von Streckdefiziten am Kniegelenk].
- [29] LaPrade RF, Pedtke AC, Roethle ST. Arthroscopic posteromedial capsular release for knee flexion contractures. *Knee Surg Sports Traumatol Arthrosc* 2008;16(5):469–75 [Epub 2008/02/20].
- [30] Louisia S, Charrois O, Beaufils P. Posterior “back and forth” approach in arthroscopic surgery on the posterior knee compartments. *Arthroscopy* 2003;19(3):321–5 [Epub 2003/03/11].
- [31] Ahn JH, Lee SH, Jung HJ, Koo KH, Kim SH. The relationship of neural structures to arthroscopic posterior portals according to knee positioning. *Knee Surg Sports Traumatol Arthrosc* 2011;19(4):646–52 [Epub 2010/12/15].